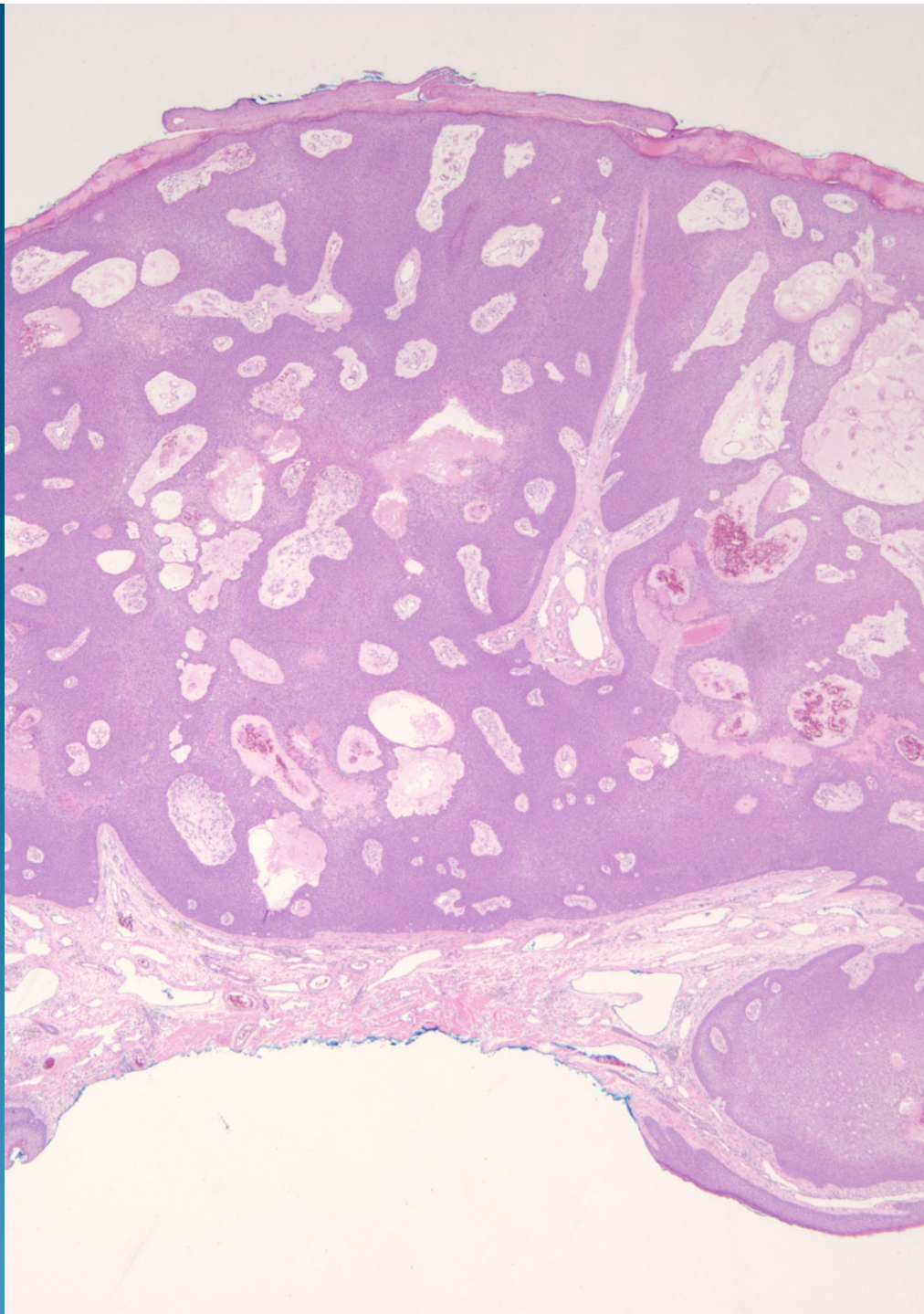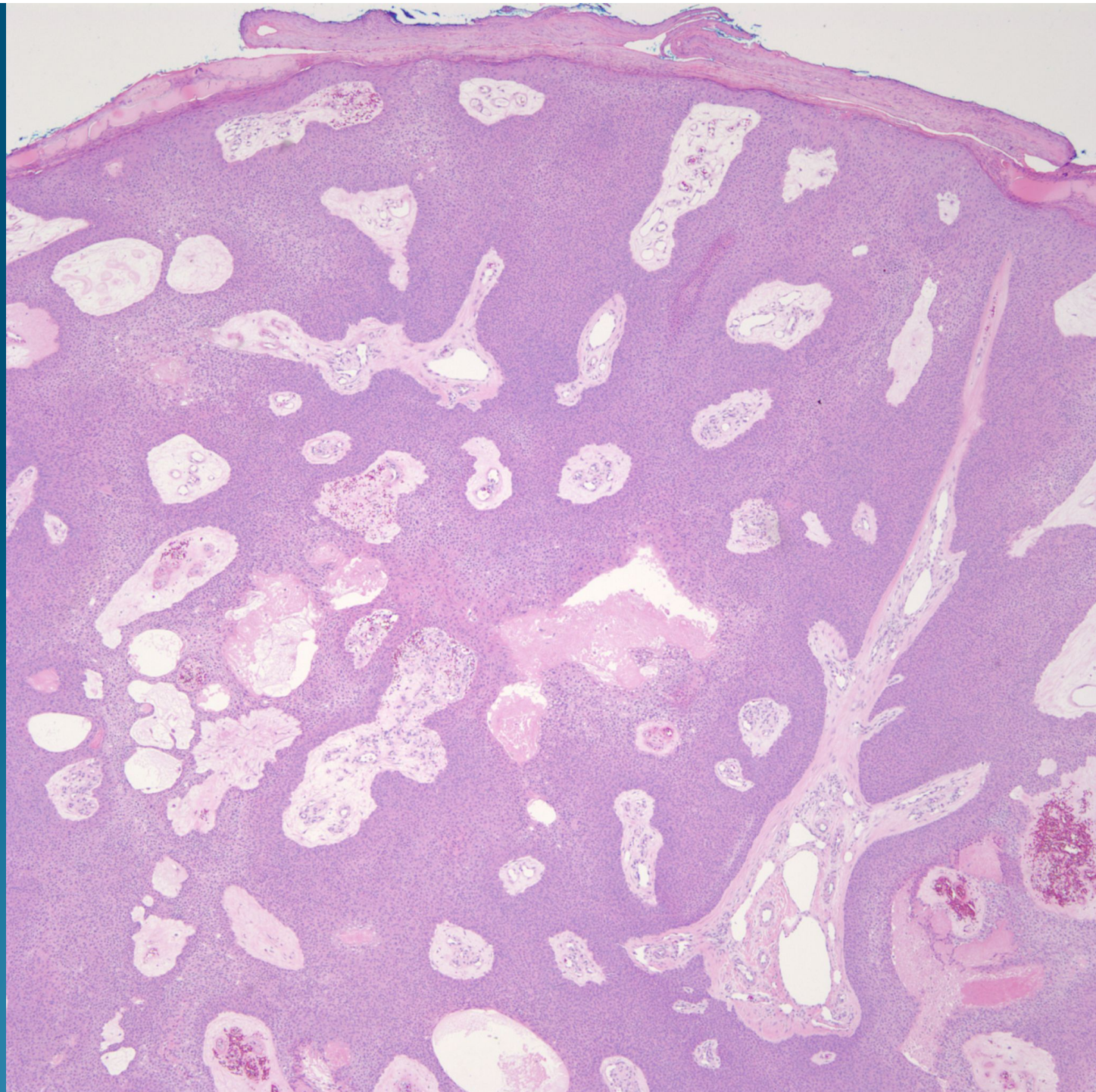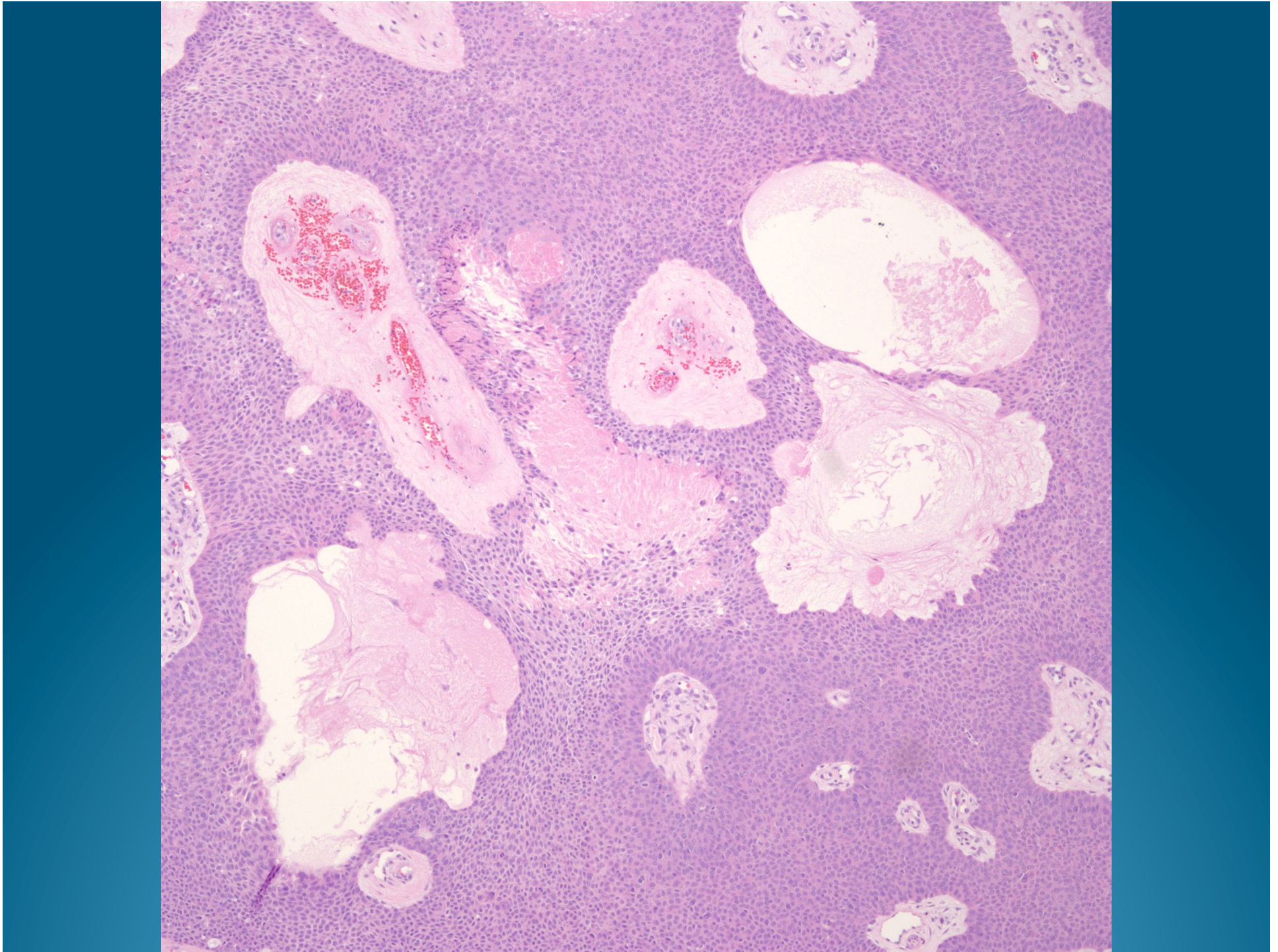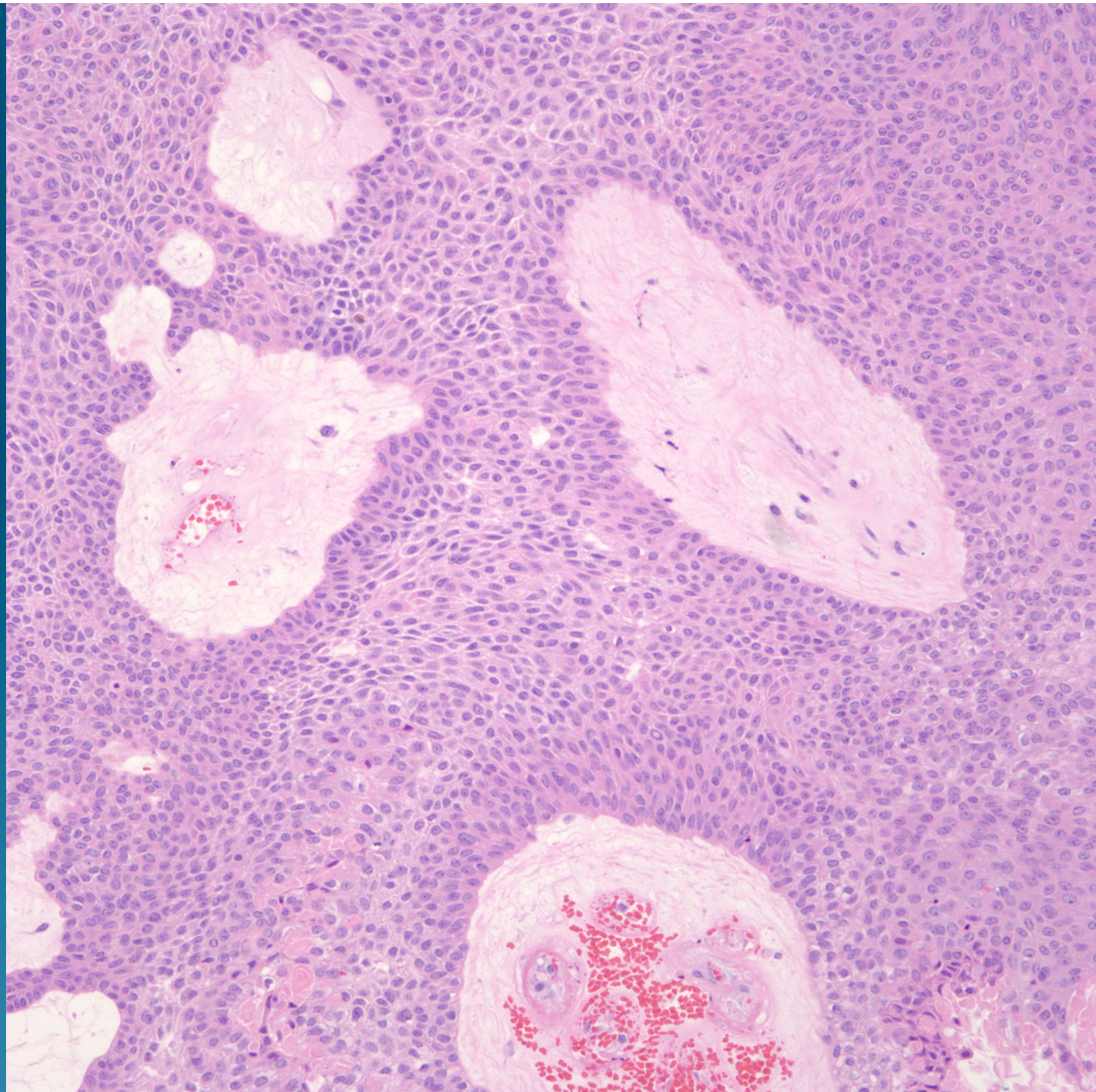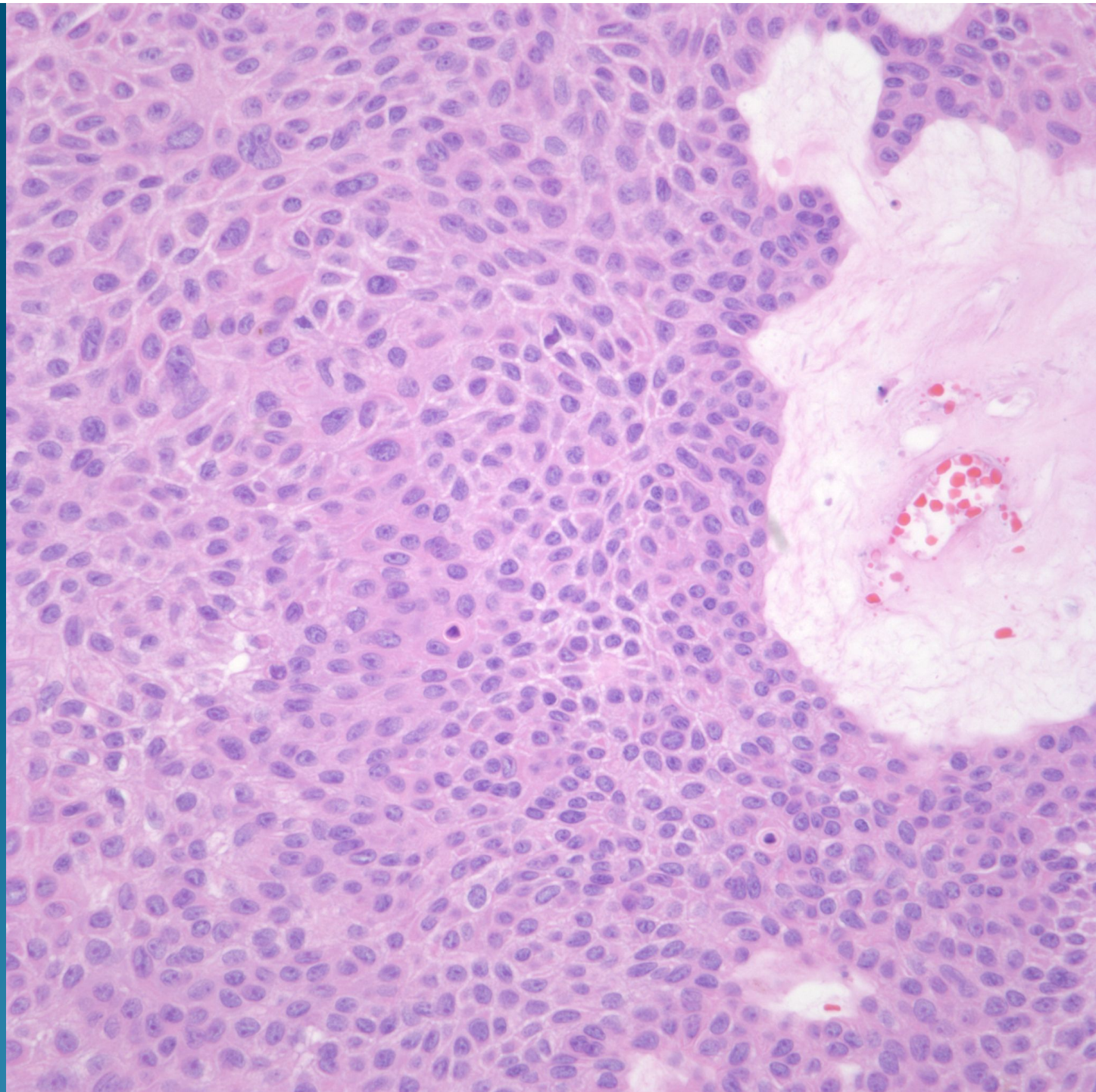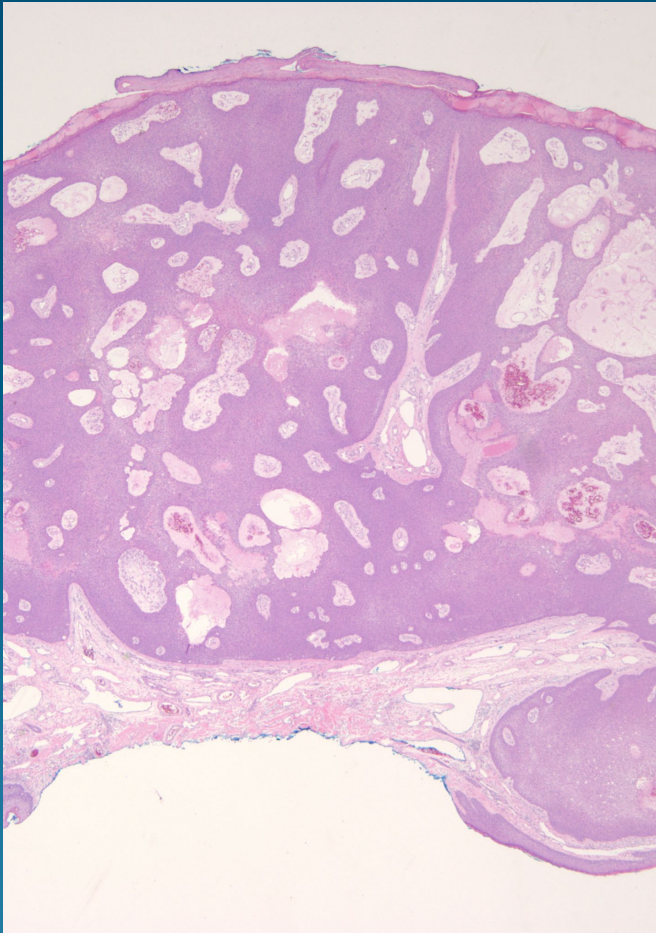


What is the best diagnosis?

- A. Seborrheic keratosis
- B. Poroma
- C. Bowen's disease
- D. Nodular basal cell carcinoma
- E. Cylindroma

Poroma

Pearls



- Circumscribed tumor connected to the epidermis
- Resembles seborrheic keratosis but usually rounded pushing border
- Hyalinization around increased vessels